

# Herpesvirus infection



# Introduction

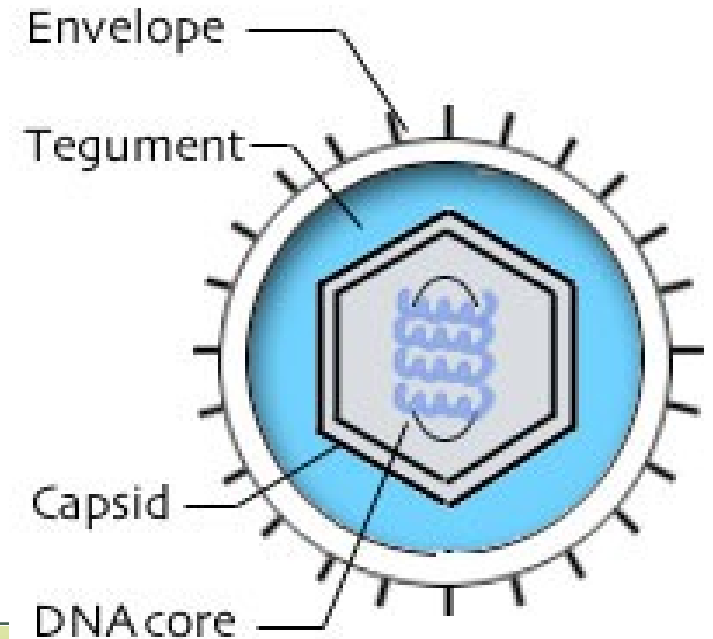
- Viruses are an important cause of illness & death in all animals including humans and macropods.
- Herpesviruses are a large family of DNA viruses.
- More than 130 Herpesviruses have been identified in mammals, birds, reptiles, amphibians, fish and molluscs.



# Herpesvirus Structure

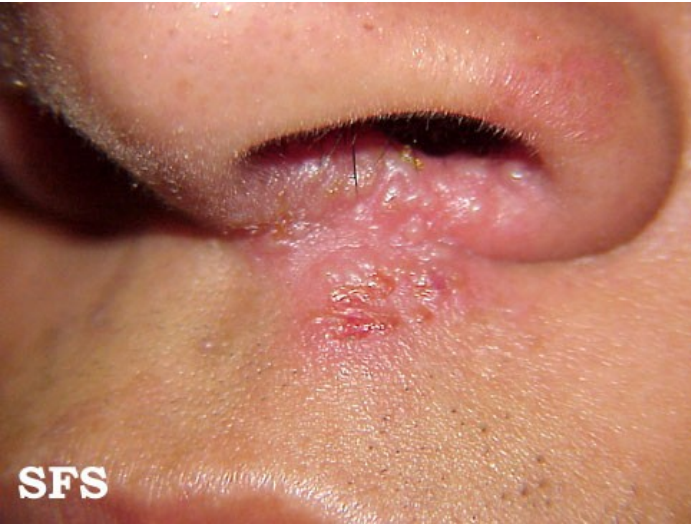- Herpesviruses are DNA viruses.
- DNA core 100-200 genes.
- Encased in protein – Capsid.
- Protein layer – Tegument.
- Envelope - lipid and glycoprotein.

## Virion



Where traumatised wildlife  
can recover in safety

# Herpesvirus Classification



- Herpesviruses are divided into three sub-families.
  - Alpha
  - Beta
  - Gamma
- Common human herpesviruses include:
  - Cold sores (HHV-1, alpha);
  - Genital Herpes (HHV-2, alpha);
  - Chicken pox/ shingles (HHV-3, alpha);
  - EBV (Glandular fever, HHV-4, gamma);
  - CMV (HHV-5, beta); and
  - Kaposi sarcoma herpesvirus (HHV-8, gamma).



Where traumatised wildlife  
can recover in safety

# Macropod Herpesviruses

- MaHV-1, alpha
- MaHV-2, alpha
- MaHV-4, alpha
- MaHV-3, gamma
- Novel Gamma Herpesvirus reported in healthy swamp wallabies (Australian Wildlife Health Network, Herpesviruses & Macropods Fact Sheet)

# Herpesvirus Lifecycle

- Envelope proteins bind to host cell receptors
- Virion enters host cell
- Viral DNA migrates to host cell nucleus
- Viral DNA replicates in the nucleus
- Viral genes transcribed
- Viral proteins produced
- Multiple virions assembled
- Host cells mostly lysed as a result of viral infection
- In some cells (and thus the host) the virus persists - termed latent
- Latent viruses can be reactivated at a later time.





# List of Macropods Reported as Hosts for Herpesviruses

- Eastern Grey (EG), Western Grey and Red Kangaroos
- Black Tree Kangaroo
- Black Wallaroo
- Swamp, Parma, Tammara and Brush-tailed Rock Wallabies
- Quokka
- Dusky Pademelon
- Brush-tailed and Rufous Bettongs
- Long-nosed Potoroo



Where traumatised wildlife  
can recover in safety

*Source: AWHN, Herpesviruses &  
Macropods Fact Sheet*

# Clinical Signs

- Discharge from nose and eyes
- Sneezing
- Fever
- Decreased appetite
- Conjunctivitis
- Keratitis (inflammation of cornea)
- Swelling of upper lip and nasal passages
- Genital ulcers
- Mouth and nasal ulcers
- Respiratory signs
- Death



Source: Ladds (2009)



# Clinical Signs Cont

- The American Association of Zoo Veterinarians Infectious Disease Committee Manual 2013 described the alphaherpesviruses as causing fatal systemic infections for which there was no known treatment.
- Based on the description in the literature of the clinical signs of both the human and macropod alphaherpesviruses we consider it likely that the virus that has affected the joeys at *Possumwood* is an alphaherpesvirus.



Source: Ladds (2009)


# Possumwood Experience: Initial Observation



- First observed 13 years ago
- Toby – 15 kg EG - homesite (soft) release
- Illness signs – sneezing, clear discharge from eyes and nostrils, vigorous nose rubbing with forepaws
- Other EG Kangaroos released with Toby were observed with the same signs (eg Lizzie)
- Uneventful recovery – no treatment required.

# Possumwood: Further Episodes

- Episodes of the same symptoms as well as fever and lethargy were occasionally observed in EG Kangaroos in enclosures at Possumwood over the next few years.
- All affected EG macropods recovered uneventfully without treatment
  - All affected macropods were  $> 5\text{kg}$ .
  - Several EG females released at Possumwood have been observed for 11 years and not had a reoccurrence of the illness.



Poppy



Where traumatised wildlife  
can recover in safety

# Possumwood: Initial Fatal Episode

- In 2011 small joeys (<3kg) were exposed to older macropods who had the virus.
- These joeys (some raised from 500gm) had no previous exposure to the herpesvirus, had immature immune systems and no protective antibodies from mother's milk.
  - One by one these joeys started to show symptoms of the herpesvirus infection.
  - 12 of the 15 joeys died despite veterinary involvement, IV antibiotics and fluids, and other supportive care.
  - The disease became known locally as kangaroo flu.





# Possumwood: Second and Final Fatal Episode

- The virus affected another group of small joeys (<3kg). Sophie the first of the group developed signs of the disease and died.
- The decision was made to trial a human herpes antiviral called Valaciclovir. This was based on: (1) observations of nasal, cloacal and eye ulcers in EG previously; (2) the correlation with similar signs in human herpesvirus infections.
  - As soon as a joey showed signs of the disease, Valaciclovir was commenced. The joeys stopped sneezing in three days and recovered uneventfully and didn't require other treatment.
  - Sophie was the last small joey to die from the herpesvirus at Possumwood.



# Virus Identification

- In 2014 Heidi (2kg EG) was observed sneezing. A viral nasal swab was taken and Valaciclovir was commenced immediately. The disease did not progress and she made a full recovery. The Herpesvirus PCR was positive for the presence of herpesvirus DNA.

Angela Begg  
Veterinary Pathologist

REFERENCE REPORT  
VETERINARY CLINIC SCHOOL - VET MISC. SENDAWAY

Herpes

Test Requested : Herpesvirus PCR

Test Result : The sample was positive for the presence of herpesvirus DNA by PCR.



Where traumatised wildlife  
can recover in safety

# Valaciclovir as Suppressive Treatment

- Small joeys being raised with Heidi were given a suppressive dose of Valaciclovir and did not develop signs of the disease.
- They appeared to develop immunity to the virus as they did not show signs of the disease when later exposed to the virus.
- Subsequently Valaciclovir has been used successfully by other local carers.



Heidi-12 months after treatment with Valaciclovir and full recovery from the herpesvirus

Spencer received suppressive treatment





# Medication

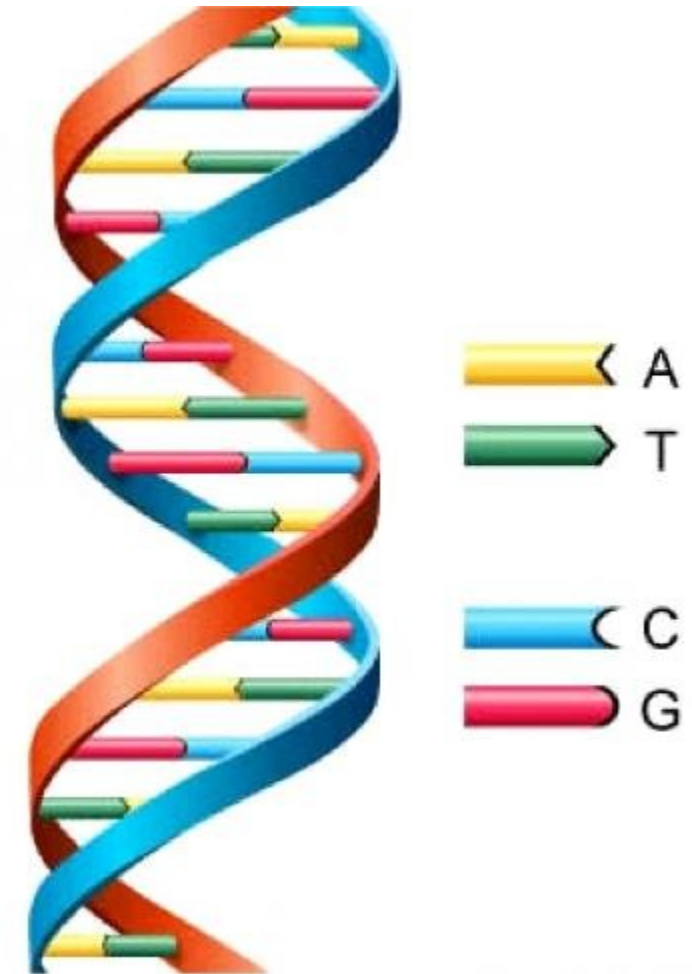
- Nucleoside Analogue antivirals

Generic	Brand	Active form in cells
Aciclovir	Zovirax	Aciclovir
Valaciclovir	Valtrex	Aciclovir
Famciclovir	Famvir	Penciclovir

- Aciclovir and Penciclovir are phosphorylated in the host cells by a herpesvirus enzyme – thymidine kinase. Hence the specificity for herpesviruses.

# Medication Cont

- The active triphosphate form of the medication competes with one of the normal bases (the building blocks for DNA) for incorporation into the DNA chain.
- The viral DNA polymerase enzyme cannot continue to elongate the DNA chain and hence viral replication stops.
  - Medication **MUST** be used early at the first sign of a herpesvirus infection – less than 48 hours after symptoms start.



# Why Valaciclovir?

- Most common herpes antiviral used in humans
- What about Famciclovir? – OTC with pharmacist advice for cold sores.
- Cost: Valaciclovir – 42 x500mg tablets for shingles is \$25 on private script; Famciclovir – 3x 500mg tablets for cold sores \$16.95 OTC.



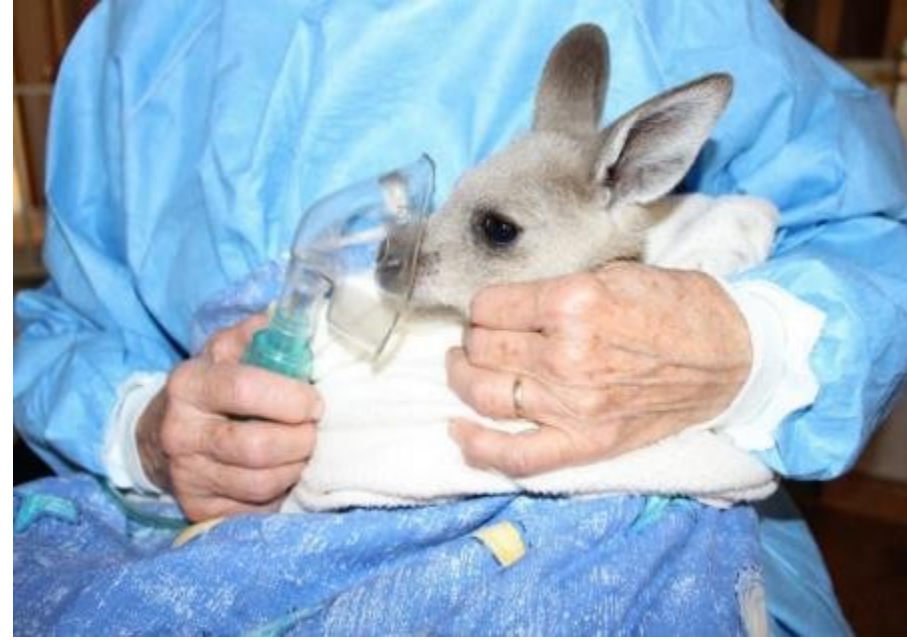# Medication Dosage

- Valaciclovir
  - Human dose for shingles is 2x500mg tablets 3xdaily (TDS) for 7 days.
  - Joey dose: Crush 1x500mg tablet and suspend in 15ml cooled boiled water. Use 0.5ml/kg of the shaken suspension TDS for 7 days. Keep in fridge for use same day. Apporox 1/ 60<sup>th</sup> of human dose.
- Famciclovir
  - Human dose for shingles is 1x250mg tablet TDS for 7 days.
  - Joey dose. Crush ¼ x 500mg tablet and prepare and use as described above.



# Supportive Care

- Joeys who have not been treated with Valaciclovir early in the illness can be treated symptomatically with the following medications – Panadol, Fess nasal saline, Bromhexine, Salbutamol (Ventolin) via nebuliser or inhaler, Amoxycillin and Sucralfate



Where traumatised wildlife  
can recover in safety



# Virus Latency

- Latency is the phase in the life cycle of certain viruses in which, after initial infection, proliferation of the virus ceases but the virus is not fully eradicated and remains dormant (latent) within the host cell.
- During viral latency there is no active viral shedding and no symptoms of disease. The virus can reactivate in the host cells due to an external activator such as stress to cause an acute infection.
- 30 rehabilitated EG kangaroos translocated to an enclosure for release site delayed release showed no evidence of herpesvirus reactivation during a 4 month quarantine period.



# Summary

- A herpesvirus infection has been identified in EG Kangaroos at *Possumwood Wildlife Recovery Centre*
- This herpesvirus infection is often fatal in small EG kangaroos (<5kg) which have an immature immune system.
- This disease can be treated with a nucleoside analogue antiviral (Valaciclovir) which is specific for herpesviruses.
  - Valaciclovir stops viral replication so it must be used early in the infection to be effective (in first 48 hours).
  - As with all antimicrobial medication, Valciclovir should be used judiciously – only in those animals at significant risk of death due to the herpesvirus infection. Healthy older EG Kangaroos do not appear to be at risk of death from this particular herpesvirus.





# References

Ladds, P. 2009. *Pathology of Australian Native Wildlife*, CSIRO Publishing.

Smith, J A, et al. 2008. *Identification and isolation of a novel Herpes virus in a captive mob of eastern grey kangaroos (Macropus Giganteus)*. Veterinary Microbiology, vol 129, pp. 236-245.

Australian Wildlife Health Network. 2013. Herpesviruses and Macropods Fact Sheet. [http://wildlifehealthaustralia.net.au/Portals/0/Documents/FactSheets/Herpesviruses%20\(Macropods\)%2012%20Feb%202013%20\(1.1\).pdf](http://wildlifehealthaustralia.net.au/Portals/0/Documents/FactSheets/Herpesviruses%20(Macropods)%2012%20Feb%202013%20(1.1).pdf) Accessed 11/ 7/2016.

American Association of Zoo Veterinarians. 2013. Infectious Disease Committee Manual. [http://c.ymcdn.com/sites/www.aazv.org/resource/resmgr/IDM/IDM\\_Macropod\\_Herpesvirus\\_201.pdf](http://c.ymcdn.com/sites/www.aazv.org/resource/resmgr/IDM/IDM_Macropod_Herpesvirus_201.pdf) Accessed 11/7/ 2016.



[www.possumwood.com.au](http://www.possumwood.com.au)



*Where traumatised wildlife  
can recover in safety*



**Thank you...**